

## 3D Stereophotogrammetry Quantitative Lip Analysis

Adam R. Sawyer · Marlene See · Charles Nduka

Received: 24 March 2008 / Accepted: 16 May 2008 / Published online: 27 June 2008  
© Springer Science+Business Media, LLC and International Society of Aesthetic Plastic Surgery 2008

### Abstract

**Background** Reduction in lip volume is a stigmata of the aging face. There are many lip augmentation techniques but very few studies analyzing how these techniques change the three-dimensional structure of the lips. Furthermore, there is no consensus about whether the lip position should be standardized to either the lips closed or parted. The aim of this study was first to obtain a three-dimensional quantitative analysis of the lips in adults and to look for sexual dimorphism and, second, to compare whether more consistent measurements of the oral region can be obtained with the mouth open compared with it closed.

**Methods** Seventy young Caucasian volunteers underwent lip dimension analysis using 3D stereophotogrammetry with lips parted and closed. Parameters measured for consistency of results were linear distances (e.g., mouth width, total lip height, upper lip height), surface distances (e.g., upper vermilion), areas (e.g., vermilion upper and lower lip, total vermilion), and volumes (upper and lower lip volume, total lip volume). Analysis also compared lip dimensions between male and female subjects.

**Results** Consistent and reproducible results were seen with the lips closed compared with lips apart. All lip parameters (distances, areas, and volumes) were larger in men than in women. The following measurements had significant differences between males and females: mouth width, upper lip height median, upper white lip height median, upper white lip height lateral, lower vermilion surface distance, and area of vermilion ( $p < 0.05$ ).

**Conclusion** We present a novel technique for aesthetic assessment of the lips that is objective and achieves consistency with the lips in the closed position. Males have greater lip dimensions compared with females.

**Keywords** Lip augmentation · Stereophotogrammetry · Lip measurement · Lip volume

The lips are an essential component of facial symmetry and aesthetics. Anthropometric studies have shown that wider and fuller lips in relation to facial width as well as greater vermilion height are a mark of female attractiveness [1]. Attention was first drawn to age-related lengthening of the upper lip by Gonzalez-Ulloa [2] in 1975. Aging changes in the lip manifest in three ways: (1) longer distance between the columellar base and upper lip vermilion border, (2) less exposed vermilion (“thin lips”), and (3) relative loss of vermilion bulk (“pout”).

There is a general demand now for bigger and fuller lips among those seeking facial cosmetic surgery. This created a surge in new surgical procedures to augment the lip that can be broadly classified into those that use local flaps of the oral mucosa and perioral skin and those that use foreign or autologous material [3–5].

Review of the literature over the past 25 years shows a multitude of case reports, innovations, and new techniques for augmenting the lip [4, 6–12] but very few studies analyzing how these new techniques change the three-dimensional structure of the lips. The assessment of lip size is challenging for both the clinician and the patient as it is largely based on subjective perception. There is therefore a need for a three-dimensional clinical record that enables precise measurement of the lips. To date there is no precise specific technique to objectively assess the size of the lips.

A. R. Sawyer (✉) · M. See · C. Nduka  
Queen Victoria Hospital, NHS Foundation Trust, Holtye Road,  
East Grinstead, West Sussex RH19 3DZ, UK  
e-mail: drasawyer@hotmail.com

Previous methods used to assess the lips have included magnetic resonance imaging, the use of a cheilometer, and clinical photography. Magnetic resonance imaging can assess soft tissue size but is expensive and has relatively poor resolution for surface changes. The cheilometer was found to produce nonreproducible results [13]. The assessment of lip size has been performed in patients with orofacial granulomatosis using impression material and callipers [13]; however, any technique that relies on making impressions risks surface distortion and introducing artifacts.

Commonly used methods for measuring the effects of lip augmentation have included using a standardized camera and ruler [14, 15]. This technique is time-consuming (since both an anterior–posterior and lateral photography views are required) and can lead to inaccurate measurement. In addition, the volume of the lips cannot be assessed. This is a particularly important variable to measure especially in the case of soft tissue fillers which do not change the shape of the lips in a predictable way. Photography does provide an overall assessment of the lips but is only semiquantitative and does not allow subtle changes to be detected. Another difficulty with images taken separately is that reproducibility may be affected by changing poses. There is no consensus about whether the lip position should be standardized to either the lips closed or parted.

The dimensions of the lips and their reciprocal spatial positions with respect to the nose and chin are important components in the clinical analysis of plastic surgery patients [16, 17]. Ideally, the quantitative assessment of the main characteristics of the human face should be a three-dimensional evaluation [18]. One such objective and quantitative method for analyzing facial dimensions is 3D stereophotogrammetry [19]. This system uses two digital camera pods to create a 3D facial image.

The aim of this study was to obtain a three-dimensional quantitative analysis of the lips in adults and to look for sexual dimorphism and to compare whether more consistent measurements of the oral region can be obtained with the mouth in the open position compared with the closed position.

## Methods

### Study Population

Seventy healthy Caucasians adults (38 men and 32 women) were assessed. The average age was 33 years (range = 21–49 years). Subjects were informed about all procedures and written consent from volunteers was obtained. Subjects excluded from the study were those who had had previous

lip augmentation, lip surgery, or clinical evidence of orthognathic deformity.

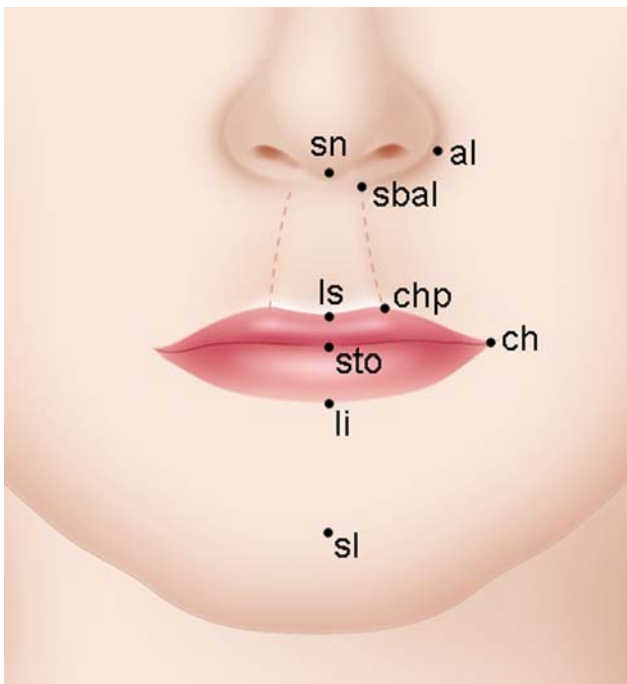
### Procedure

The study had local ethics committee approval. Each subject was imaged using the VECTRA-3D dual module system (Canfield Scientific, Inc., Fairfield, NJ, USA), which uses stereophotogrammetry (Fig. 1). The 3D stereophotogrammetry we used was supplied by Surface Imaging International Ltd, UK. The 3D stereophotogrammetry system integrates two pods, each with three cameras; on either side two monochrome cameras are synchronized to capture images illuminated by integral projectors. The camera system required calibration each day before capturing facial data. The 3D facial model that is generated can be analyzed using VAM<sup>®</sup> (visualization, analysis, measurement) application software. Because it is a digital facial model, one is able to rotate, pan, or zoom into the images and view multiple surfaces simultaneously to facilitate analysis.

The subjects were imaged with the mouth closed and open. All recordings were completed by a single investigator who instructed the subject to pose with lips just closed and with the lips just parted to obtain the closed mouth and open mouth positions. Images were analyzed by a single investigator. Each landmark was positioned according to those described by Farkas [20]. For each subject the following landmarks were placed: right and left cheilion (chR and chL), labiale superius (ls), labiale inferius (li), subnasale (sn), sublabiale (sl), stomonium (sto), right and left alar (alR and alL) christa philtri (chpR and chpL), and right and left subalare (sbalR and sbalL) (Fig. 2). A reference line (line 3) was drawn from the left and right subalare so that the upper white height lateral could be calculated (Fig. 3). From this the following parameters were calculated:



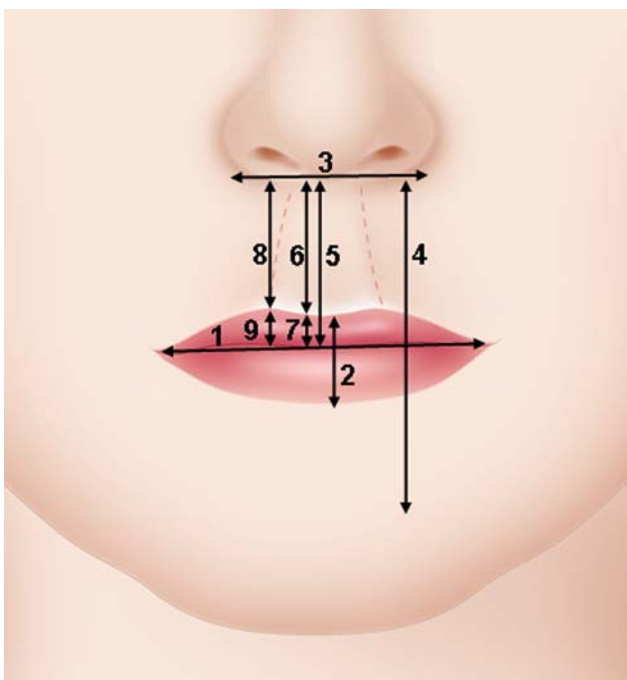
**Fig. 1** VECTRA-3D dual module stereophotogrammetry system



**Fig. 2** Facial landmarks used in this study for quantitative analysis of the lips

(A) Linear distances (mm) (Fig. 3)

1. mouth width (chR – chL)
2. total vermilion height (ls – li)
3. base nose width (alR – alL)
4. total lip height (sn – sl)



**Fig. 3** Linear distances measured

5. upper lip height median (sn – sto)
6. upper white lip height median (sn – ls)
7. upper red lip height median (sl – sto)
8. upper white lip height lateral (reference line – chp)
9. upper red lip height lateral (chp – sto)

(B) Surface distance (mm) (Fig. 4)

1. upper vermilion surface distance (sn – sto)
2. lower vermilion surface distance (sto – li)

(C) Ratios (%)

1. vermilion height to mouth width  $(ls-li / chR-chL \times 100)$

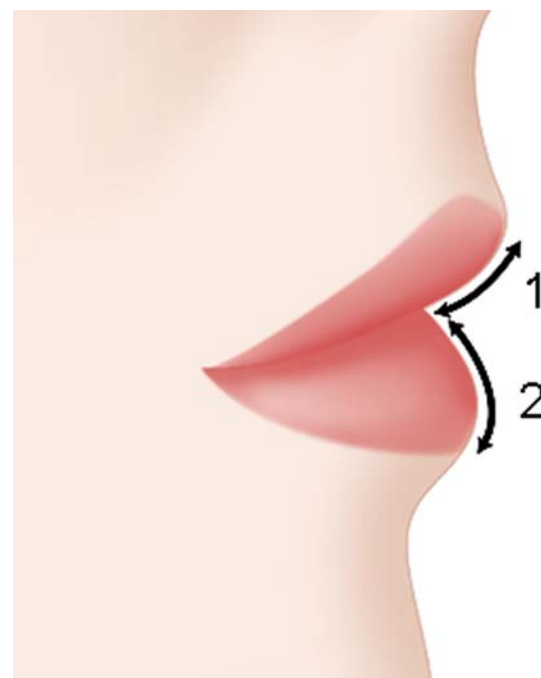
(D) Areas (cm<sup>2</sup>) (Fig. 5)

1. upper lip vermilion area (A)
2. lower lip vermilion area (B)

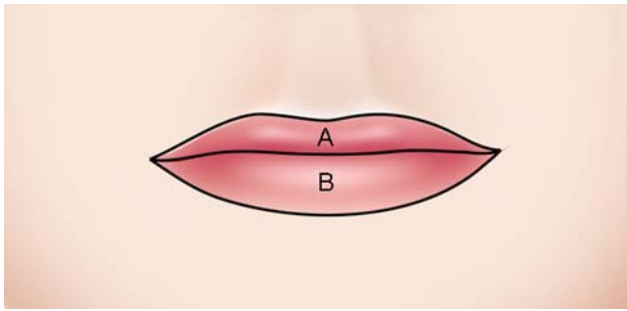
(E) Volumes (cm<sup>3</sup>)

1. upper lip volume
2. lower lip volume
3. total lip volume

Statistical analysis included mean, standard deviation, and ratios that were calculated for the whole group and for each sex. Student's *t* test was used for independent-samples measuring between sexes. Significance was set at 5% ( $p < 0.05$ ). To compare variability of the results between



**Fig. 4** Lateral view of the lips to show upper/lower surface distance measurement

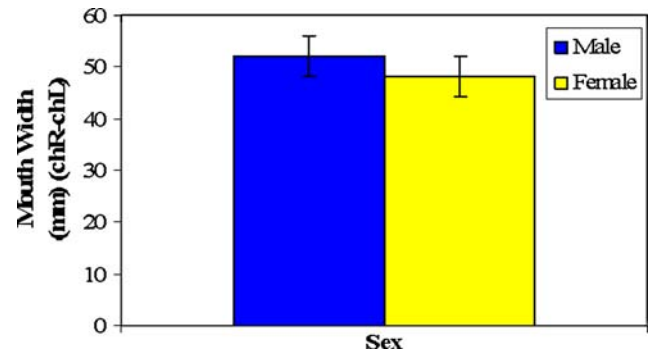


**Fig. 5** Area measured for upper/lower lip vermilion

the closed lip and open lip positions, standard deviation and ranges are shown.

## Results

The results of the linear and surface distance measurements and vermilion height-to-mouth width ratio of the lips in the closed position in healthy adults are given in Table 1. Table 1 gives the mouth width, total lip height, upper lip height median, upper white lip height median, upper white height lateral, and lower vermilion surface distance, which all showed significant differences between males and females, with males having consistently larger lip proportions. Table 1 also shows that total vermilion height and



**Fig. 6** Difference in mean mouth width in males and females ( $p < 0.05$ )

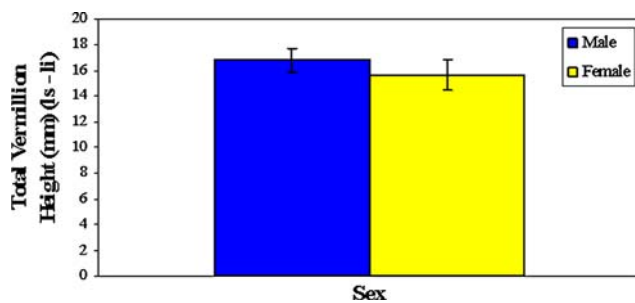
base of nose width approach significant differences between males and females ( $p = 0.07$  and  $p = 0.06$ , respectively). However, there was no significant difference in the upper red lip height median, upper red lip height lateral, upper vermilion surface distance, and vermilion height-to-mouth width ratio between males and females.

Figure 6 is a graphical representation of the mean difference (with standard deviation) in mouth width between males and females. There was a significant difference in mouth width between males and females ( $p < 0.05$ ).

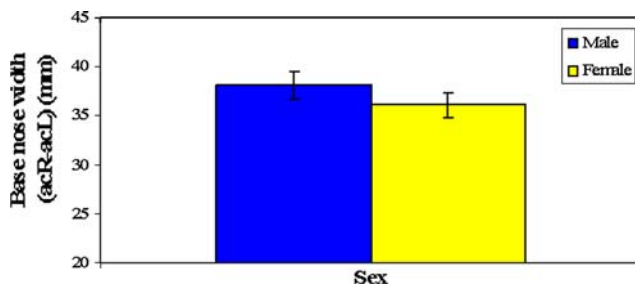
Figure 7 is a graphical representation of the mean vermilion height in males and females; the difference approaches significance.

**Table 1** Mean linear and surface distances with standard deviation with lips in the closed position

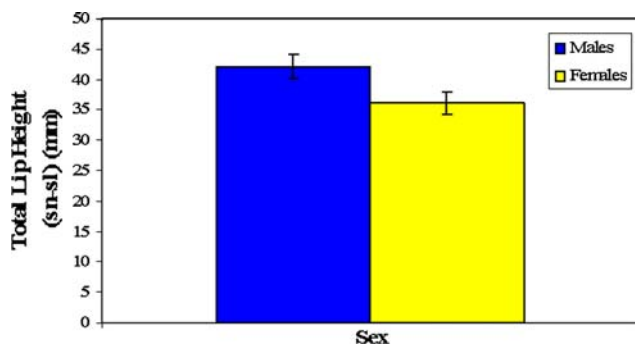
Facial measurement (with lips closed)	All subjects		Male (mm)	Female (mm)	Significance M vs. F
	Mean	SD			
Mouth width (chR – chL) (mm)	50.1	4.1	52.2	48.1	$p < 0.05$ Fig. 6
Total vermilion height (ls – li) (mm)	16.2	3.2	16.8	15.7	$p = 0.07$ Fig. 7
Base nose width (alR – alL) (mm)	37.3	3.1	38.1	36.1	$p = 0.06$ Fig. 8
Total lip height (sn – sl) (mm)	39.9	3.8	42.1	36.1	$p < 0.05$ Fig. 9
Upper lip height median (sn – sto) (mm)	20.6	2.7	21.3	19.2	$p < 0.05$ Fig. 10
Upper white lip height median (sn – ls) (mm)	15.0	2.8	15.7	13.6	$p < 0.05$
Upper red lip height median (sl – sto) (mm)	5.6	1.6	5.6	5.6	$p = 0.8$
Upper white lip height lateral (reference line to chp) (mm)	16.0	2.7	17.0	15.0	$p < 0.05$
Upper red lip height lateral (chp – sto)	7.2	1.5	7.1	7.2	$p = 0.8$
Upper vermilion surface distance (ls-sto) (mm)	9.4	1.2	10.1	9.0	$p = 0.3$ Fig. 11
Lower vermilion surface distance (sto – li) (mm)	10.4	1.1	10.8	8.4	$p < 0.05$ Fig. 11
Vermilion height to mouth width ratio (%)	32.3	n/a	32.1	32.6	$p = 0.61$



**Fig. 7** Difference between the mean vermilion height in males and females ( $p = 0.07$ )



**Fig. 8** Difference between the mean base nose width in males and females ( $p = 0.06$ )



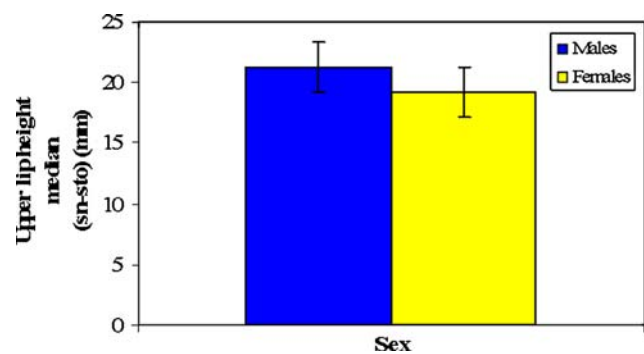
**Fig. 9** Difference between mean total lip height in males and females ( $p < 0.05$ )

Figure 8 shows the difference between male and female mean base of nose width. Note that this approaches significance ( $p = 0.06$ ).

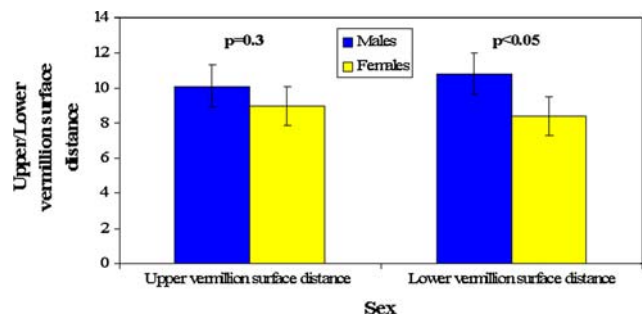
Figure 9 shows the mean differences between male and female mean total lip height. There are significant differences between males and females.

Figure 10 shows the difference between the mean upper lip height median in males and females which is significantly different.

Figure 11 shows the difference in upper/lower vermilion surface distances in males and females. There was no significant difference between the upper vermilion surface distance in males and females; however, there was a significant difference between the lower vermilion surface distance in males and females.



**Fig. 10** Difference between mean upper lip height median in males and females ( $p < 0.05$ )



**Fig. 11** Difference between upper/lower vermilion surface distance for males and females. Note only significant difference between males and females in the lower vermilion surface distance

The areas and volumes of the closed lips in healthy adults are given in Table 2.

The average areas of the upper lip and the lower lip were 2.6 cm<sup>2</sup> and 2.5 cm<sup>2</sup>, respectively. There was a significant difference between the upper and lower lip areas when comparing males and females. The volumes of the upper lip and the lower lip were 3.0 cm<sup>3</sup> and 2.8 cm<sup>3</sup>, respectively. There was no significant difference in the volumes of the upper and lower lip vermilions between males and females.

Analysis of the lip linear distances, surface distances, areas, and volumes of lips is given in Table 3 with the mouth in the open position (please note that male and female averages are not shown because of the greater inaccuracy when measuring the mouth in the open position, see below).

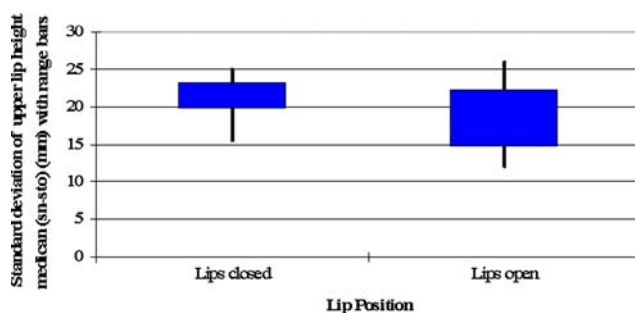
When the mouth was open the data collected showed significant variation, even with a single operator. As you can see by comparing Tables 1 and 2 (closed lip position) with Table 3 (open mouth position), there was a greater standard deviation with the mouth in the open position. This is better seen graphically. Figure 12 shows a box graph with standard deviation from the median and range bars for upper lip height in the closed and open mouth

**Table 2** Mean areas and volumes with standard deviation of lips in the closed position

Facial measurement (with lips closed)	All subjects		Male	Female	Significance M vs. F
	Mean	SD			
Area of vermilion upper lip (cm <sup>2</sup> )	2.6	0.8	2.8	2.3	$p < 0.05$
Area of vermilion lower lip (cm <sup>2</sup> )	2.5	0.8	2.9	2.3	$p < 0.05$
Volume of upper vermilion (cm <sup>3</sup> )	3.0	0.7	3.0	2.8	$p = 0.1$
Volume of lower vermilion (cm <sup>3</sup> )	2.8	0.8	2.9	2.7	$p = 0.1$
Total volume of vermilion (cm <sup>3</sup> )	5.8	0.91	5.9	5.5	$p = 0.07$

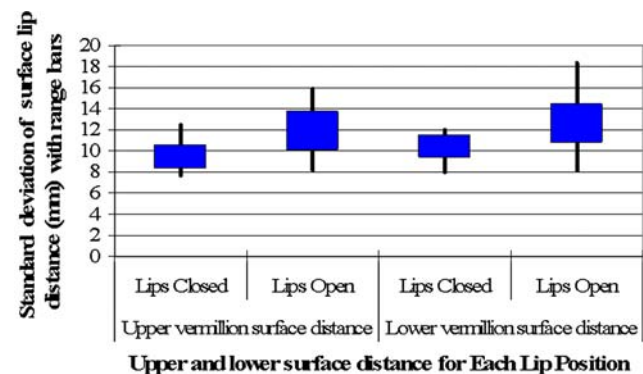
**Table 3** Linear and surface distances, standard deviation, and range with lips in open position

Facial measurement (with lips in open position)	All subjects		Range
	Mean	SD	
Mouth width (chR – chL) (mm)	45.1	7.1	36.1–55.1
Total vermilion height (ls – li) (mm)	n/a as open mouth	n/a as open mouth	n/a as open mouth
Base nose width (alR – alL) (mm)	37.1	3.2	29.9–40.1
Total lip height (sn – sl) (mm)	n/a as open mouth	n/a as open mouth	n/a as open mouth
Upper lip height median (sn – sto) (mm)	18.4	3.8	12.0–25.1
Upper white lip height median (sn – ls) (mm)	15.0	3.5	12.1–22.2
Upper red lip height median (sl – sto) (mm)	7.8	3.0	3.2–10.5
Upper white lip height lateral (reference line to chp) (mm)	16.0	3.4	13.2–24.2
Upper red lip height lateral (chp – sto) (mm)	8.2	2.7	4.1–11.9
Upper vermilion surface distance (ls – sto) (mm)	11.9	1.9	8.1–15.9
Lower vermilion surface distance (sto – li) (mm)	12.6	1.9	8.1–18.3
Area of vermilion upper lip (cm <sup>2</sup> )	3.1	1.3	1.9–4.1
Area of vermilion lower lip (cm <sup>2</sup> )	3.5	1.2	2.2–5.1
Volume of upper vermilion (cm <sup>3</sup> )	3.7	1.1	1.9–5.0
Volume of lower vermilion (cm <sup>3</sup> )	3.7	1.0	2.0–5.1

**Fig. 12** Box graph to show variation in measuring upper lip height median with lips in the closed/open position. Blue box refers to a standard deviation either side of the median and bars refer to range of data

positions. This shows that the standard deviation and the range of the upper lip height is much narrower with lips in the closed position.

Figure 13 shows a box graph with the standard deviation from the median and range bars for upper and lower

**Fig. 13** Box graph to show variation in upper/lower surface lip distance in the closed/open position. Blue box refers to a standard deviation either side of the median and bars refer to range of data

surface lip distance. This graph shows that the standard deviation and range bars are narrower for the lips closed position.



All other variables (including areas and volumes) measured showed that the standard deviation and range were greater when measurements were performed with the lips open compared with lips closed (therefore, no graphs are given to illustrate this).

## Discussion

There have been few attempts to quantify the effects of lip augmentation. A review of the literature over the past 25 years shows plenty of case reports, innovations, and new techniques for augmenting the lip [4, 6–12], but there have been very few studies analyzing how these new techniques change the three-dimensional structure of the lips. Many of the studies that have looked at lip morphology changes after augmentation have used a subjective analysis such as a surgeon's "eye" rather than an objective analysis.

The lips are an essential component of facial symmetry and aesthetics [15] and this study reports a reproducible and accurate method for assessing lip morphology. Three-dimensional stereophotogrammetry allows rapid, noninvasive, and accurate assessments of the soft tissues of the face with respect to linear distances, surface distances, and areas and has also proven to be accurate at assessing volumes [21]. A further important feature of 3D stereophotogrammetry is that the imaging system is independent of head posture. One of the negative aspects of 3D stereophotogrammetry is that accurate assessment of dimensions requires the investigator to place the landmarks (e.g., chelion) accurately. We have found in an unpublished pilot study that this can be done to within 0.8–1.1 mm.

Measurements of mouth width (chR – chL), total vermilion height (ls – li), upper lip height (sn – sto), total lip height (sn – sl), upper vermilion surface distance (ls – sto), and lower vermilion surface distance (sto – li) with the lips in the closed position using stereophotogrammetry are similar to those observed using direct anthropometry [20–22] and with previous published data collected using three-dimensional techniques [23].

A search of the literature found no study that looked at surface distance lip assessment. Previous investigators who have looked at upper and lower lip projection [14, 15] have used a reference line starting at the nasal tip to the soft tissue pogonion; the line drawn from the vermilion meets the reference line at an angle of 90°. This technique is obviously time-consuming and we suggest that using the surface distance of the upper lip vermilion from the lateral side will give an adequate indication of whether there has been any change in lip projection.

Stereophotogrammetry produces a good approximation of lip volume, but it is difficult to produce an accurate lip volume because it depends on where the three dimensions

of the lip are defined. However, stereophotogrammetry is good at comparing changes in volume in the same individual. This may be particularly important in quantitative analysis of procedures that augment the lips using soft tissue fillers where there are clearly changes in the fullness of lips but the changes in the shape of the lips is not always predictable.

Significant differences were seen between sexes in the linear and surface measurements and the area of the vermilion; several investigators also found the same results [20–24]. Male values are consistently larger than female values. The mouth ratio (a rough assessment of mouth form) showed no sexual dimorphism, which is consistent with other studies [23].

With the mouth in the open position, changes in posture obviously changed the differences in the lip dimensions. The investigator observed that there was significant variability in the results collected with the mouth in the open position. An example of this was when measuring the upper/lower surface lip distance. It was difficult to assess this distance because although the vermilion border itself is an easily identifiable landmark, the surface of the vermilion is more difficult to assess and this led to inconsistencies in measurements. This was also seen for any measurement that included the stomion (sto), such as the upper lip height median (Fig. 12).

There were also inconsistencies with area and volume of the vermilion measured with the mouth in the open position. These inconsistencies were caused by the lack of clarity between the wet–dry mucosa junction. Discrepancies in measurements taken with relaxed lips, closed lips, and lips with several degrees of contraction have also been reported before [25]. As a result of these inconsistencies we suggest that when assessing lip dimensions, the lips should be in the closed position because assessment of the lips in this position was much more consistent.

The aging lip can be rejuvenated with a variety of surgical techniques and we suggest that 3D stereophotogrammetry is a useful tool in the assessment of lip dimensions when the lips are in the close position. Stereophotogrammetry could be used clinically in the assessment of the augmented lip, in particular, when looking at the longevity of soft tissue augmentation and the effects of lip fillers. Furthermore, the better we know how a particular lip procedure changes with a particular aspect of lip appearance, the more the plastic surgeon will be able to tailor lip surgery, whether it be for the atrophic senile lip or the normal lips of young patients requesting aesthetic enhancement. In addition, stereophotogrammetry may also be used to evaluate treatment-related morphologic changes in soft tissues, such as orofacial granulomatosis.

In conclusion, the results of the present study suggest that 3D stereophotogrammetry is a simple and reliable

technique for the routine evaluation and quantification of the size of lips and gives a basis for normal lip dimensions in the healthy Caucasian population. In addition, we suggest that imaging of the lip should be performed with the lips in the closed position.

## References

- Farkas LG, Kolar JC (1987) Anthropometrics and art in the aesthetics of women's faces. *Clin Plast Surg* 14(4):599–616
- Gonzalez-Ulloa M (1975) Transactions of the sixth international congress of plastic and reconstructive surgery: the aging upper lip. Masson, Paris
- Aiache AE (1991) Augmentation cheiloplasty. *Plast Reconstr Surg* 88(2):222–226
- Austin HW (1986) The lip lift. *Plast Reconstr Surg* 77(6):990–994
- Lassus C (1981) Thickening the thin lips. *Plast Reconstr Surg* 68(6):950–952
- de Benito J, Fernandez-Sanza I (1996) Galea and subgalea graft for lip augmentation revision. *Aesthetic Plast Surg* 20(3):243–248
- Chajchir A, Benzaquen I (1989) Fat-grafting injection for soft-tissue augmentation. *Plast Reconstr Surg* 84(6):921–934; discussion 935
- Fanous N (1984) Correction of thin lips: "lip lift." *Plast Reconstr Surg* 74(1):33–41
- Hinderer UT (1995) Aging of the upper lip: a new treatment technique. *Aesthetic Plast Surg* 19(6):519–526
- Linder RM (1992) Permanent lip augmentation employing polytetrafluoroethylene grafts. *Plast Reconstr Surg* 90(6):1083–1090; discussion 1091–1092
- Samiian MR (1993) Lip augmentation for correction of thin lips. *Plast Reconstr Surg* 91(1):162–166
- Tobin HA, Karas ND (1998) Lip augmentation using an alloderm graft. *J Oral Maxillofac Surg* 56(6):722–777
- Chiandussi S, Tappuni AR, Watson TF, White A, Escudier MP, Sanderson JD, Challacombe SJ (2007) Lip impressions: a new method for monitoring morphological changes in orofacial granulomatosis. *Oral Dis* 13(1):93–98
- Sclafani AP, Romo T 3rd, Jacono AA (2002) Rejuvenation of the aging lip with an injectable acellular dermal graft (Cymetra). *Arch Facial Plast Surg* 4(4):252–257
- Jacono AA, Quatela VC (2004) Quantitative analysis of lip appearance after V-Y lip augmentation. *Arch Facial Plast Surg* 6(3):172–177
- Lundstrom A, Forsberg CM, Peck S, McWilliam J (1992) A proportional analysis of the soft tissue facial profile in young adults with normal occlusion. *Angle Orthod* 62(2):127–133; discussion 133–134
- Skinazi GL, Lindauer SJ, Isaacson RJ (1994) Chin, nose, and lips. Normal ratios in young men and women. *Am J Orthod Dentofacial Orthop* 106(5):518–523
- Ferrario VF, Sforza C, Serrao G, Miani A Jr (1995) A computerized non-invasive method for the assessment of human facial volume. *J Craniomaxillofac Surg* 23(5):280–286
- See MS, Miedzianowski-Sinclair NA, Roberts N, Nduka C (2007) Stereophotogrammetric measurement of the nasolabial fold in repose: a study of age and posture-related changes. *Eur J Plast Surg* 29:387–393
- Farkas L (1994) Examination. In: Farkas LG (eds), *Anthropometry of the head and face*, 2nd edn. Raven Press, New York, pp 23–44
- Ardehali B, Nouraei SA, Van Dam H, Dex E, Wood S, Nduka C (2007) Objective assessment of keloid scars with three-dimensional imaging: quantifying response to intralesional steroid therapy. *Plast Reconstr Surg* 119(2):556–561
- Peck S, Peck L (1995) Selected aspects of the art and science of facial esthetics. *Semin Orthod* 1(2):105–126
- Ferrario VF, Sforza C, Schmitz JH, Ciusa V, Colombo A (2000) Normal growth and development of the lips: a 3-dimensional study from 6 years to adulthood using a geometric model. *J Anat* 196(Pt 3):415–423
- Scheiderman G, Bell WH, Legan HL et al (1980) Cephalometric analysis of dentofacial normals. *Am J Orthod* 78(4):404–420
- Burstone C (1967) Lip posture and its significance in treatment planning. *Am J Orthod* 53:226–235